



Scrotal Orchiopexy (Bianchi Method): An Alternative Surgical Technique for Undescended Testicles

Kenan Yalcin, Engin Kolukcu, Fatih Firat

Tokat Gaziosmanpasa University Faculty of Medicine, Department of Urology, Tokat, Turkey

Abstract

Aim: Palpable undescended testis (PUT) is a common urological condition. This study evaluated the surgical outcomes of patients who underwent a single transverse scrotal incision for PUT. We hypothesized that scrotal orchiopexy is an effective and safe surgical procedure for PUT.

Methods: The data of 212 patients who underwent scrotal orchidopexy for PUT between 2018 and 2022 at our clinic were retrospectively analyzed. Unilateral cases of PUT located between the outer and inner inguinal rings or distal to the outer inguinal ring were included in the study. The analysis also considered postoperative complications and final cosmetic outcomes.

Results: The average age of the patients was 3.26 years. Of these, 112 (52.8%) cases were right-sided. A hernia sac was present in 168 (79.2%) patients. The testis was located distal to the outer ring in 150 (70.8%) cases and between the outer and inner rings in 62 (29.2%) cases. Postoperative complications included scrotal edema in 8 (3.8%), wound infection in 5 (2.4%) cases, and recurrence of testicular ascent in 3 (1.4%). Cosmetic satisfaction was reported by the families of 208 patients (98.1%).

Conclusion: Scrotal orchiopexy is an effective technique for managing PUT located between the outer and inner inguinal rings or distal to the outer inguinal ring.

Keywords: Scrotal incision, orchidopexy, undescended testis, children

Introduction

Undescended testis (UT) is a prevalent congenital anomaly in male neonates (1). UT is observed in 1%–4.6% of full-term male babies by the age of 1 year (2). This rate is significantly higher in premature boys, with approximately one-third of them having UT on at least one side (3). Approximately 80% of the UT cases are considered palpable and are typically located at the external inguinal ring, upper scrotum, or inguinal canal location (1). Traditional inguinal orchiopexy, which requires two incisions, is an established technique that is considered the standard for the treatment of UT. This process allows for adequate mobilization of the testes and spermatic vessels and ligation of the associated hernia (1,4). However, the most significant complications following orchidopexy include psychological problems, testicular atrophy, increased cancer risk, and infertility rate (5).

To reduce the potential morbidity associated with the combined method, Bianchi and Squire described a technique in 1989 that could be performed through a single scrotal incision (6). This technique is claimed to have the advantages of a single incision, shorter surgical time, ease of dissection, faster recovery, less pain, good preservation of testicular position, and excellent cosmetic results (7).

Palpable undescended testis (PUT) is a common urological condition. Traditional orchidopexy is widely performed in many clinics for the treatment of this pathology. In this study, we aimed to evaluate the results of scrotal orchidopexy (Bianchi method) performed with a single high transverse scrotal incision in cases where the PUT is located between the outer and inner inguinal rings or distal to the outer inguinal ring.

Address for Correspondence: Kenan Yalcin, Tokat Gaziosmanpasa University Faculty of Medicine, Department of Urology, Tokat, Turkey

E-mail: krsyalcin@yahoo.com **ORCID:** orcid.org/0000-0003-3560-5862

Received: 25.06.2024 **Accepted:** 15.12.2024



Materials and methods

Compliance with Ethical Standards

The study was approved by the Tokat Gaziosmanpasa University Faculty of Medicine, Clinical Research Ethics Committee (Approval date and number: 18.04.2024/24-KAEK-147).

Study Design

Bilateral PUT cases, those previously operated on the same side, and those located at the inner inguinal ring were excluded from the study. Unilateral PUTs located between the outer and inner inguinal rings or distal to the outer inguinal ring were included. Data from 212 patients who satisfied the criteria were evaluated.

We conducted a retrospective study from 2018 to 2022 of patients with PUT treated with scrotal orchidopexy. Medical reports of patients who underwent surgical intervention were retrospectively analyzed. The study was conducted in accordance with the Declaration of Helsinki. While recording patient data, patients were informed that these data would be used for scientific purposes, and written informed consent was obtained from each patient.

All patients who underwent surgery for PUT had the following data recorded: age, operation time, presence of hernia sac, side of undescended testicle, number of cases of testicular ascent, testicular atrophy, other complications, and cosmetic satisfaction recorded.

Surgical Technique

General anesthesia with endotracheal intubation or laryngeal mask was administered. All patients received prophylactic third-generation cephalosporin (50-100 mg/kg). The examination of the undescended testicles of the patients is performed again under anesthesia for preliminary evaluation. In this technique, the testes are brought out through the incision line at the upper border of the scrotum, parallel to the scrotal skin fold. After dissecting cremasteric fibers, vascular structures and the vas deferens are exposed. Gubernacular attachments are divided if present. The processus vaginalis is then ligated and separated at the level of the outer inguinal ring. Finally, the testis was fixed into the dartos pouch using an absorbable suture from the scrotal skin to the tunica albuginea at the base of the appendix. The dartos fascia was reapproximated, and a subcuticular closure was performed.

It was noted that in most cases, dissection within the canal could be performed solely through externalization without the need to open the anterior wall of the inguinal canal, allowing for ligation and separation of the processus vaginalis, similar to that in inguinal orchidopexy. Moreover, if sufficient cord length could not be achieved, a second incision in the inguinal region could be easily performed.

Nevertheless, a second incision was not necessary in any of the patients (Figure 1).

A total of 212 cases underwent scrotal orchidopexy surgery for PUT. Patients who were followed up in the hospital for 1 day after the operation were examined again before discharge and were discharged with appropriate treatment. A check-up was recommended 1 week later. All patients were followed up at 1, 3, and 12 months after surgery. During follow-ups, testis sizes, potential early and late complications, and cosmetic satisfaction of the families were recorded.

Figure 2. The flow chart shows the participant selection.

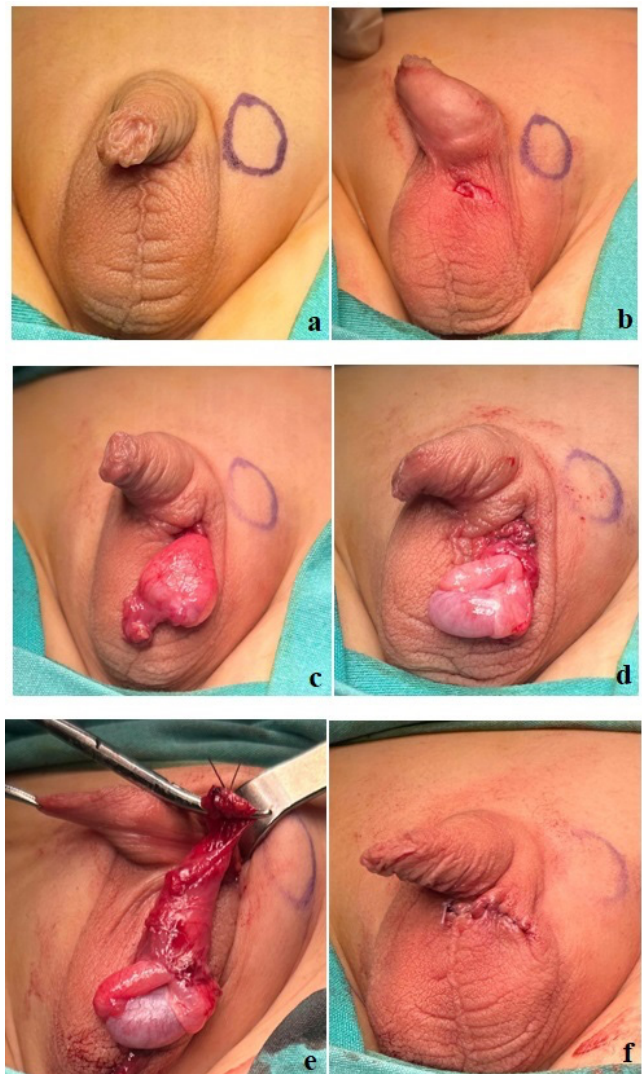


Figure 1. Stages of Scrotal Orchiopexy Operation. A. Preoperative image showing the presumed locations of the external inguinal ring and testes. B. A preoperative image showing the presumed location of the scrotal incision. C-E. Intraoperative appearance of scrotal orchidopexy. F. Final cosmetic image

Statistical Analysis

Statistical analyses were performed using the MedCalc (version 20.009; Ostend, Belgium) statistical package program. The number, mean, SD, frequency, percentage, median, 25th, and 75th percentile values were used to describe the data statistically. In the evaluation of the numerical data, the Kolmogorov-Smirnov test was used to determine whether the groups conformed to the normal distribution. Fisher's exact test was used to evaluate categorical data. Significance level $p < 0.05$ was taken for the interpretation of the results. Groups were presented graphically in the form of stacked percentage column charts.

Results

The mean age of the 212 patients who underwent scrotal orchidopexy was 3.26 years (1-8), and the mean operation time was 23.3 minutes. Of these, 112 (52.8%) cases were right-sided. A hernia sac was present in 168 (79.2%) and absent in 44 (20.8%) patients. The testis was located distal to the outer ring in 150 (70.8%) cases and between the outer and inner rings in 62 (29.2%) cases. Postoperative complications included scrotal edema in 8 (3.8%), wound infection in 5 (2.4%) cases, and recurrence of testicular ascent in 3 (1.4%). Testicular atrophy was not observed in any patient during follow-up at 1, 3, and 12 months postoperatively. However, no long-term complications or recurrences were observed during the 1-year follow-up period. In 208 patients (98.1%), cosmetic

satisfaction was reported within the families (Table 1). No groin incision was performed in any patient. Statistically significant relationships were found between the location of the UT and its inguinal position as well as the presence of a hernia sac among patients who underwent scrotal orchiopexy. Specifically, the frequency of hernias was notably high in cases where the testis was located between the outer and inner rings. ($p < 0.001$) (Table 2).

All cases of scrotal edema and wound infection were resolved with medical treatment. Protrusions of the testicle were re-operated with the same scrotal incision and were then fixed to the scrotal sac. No groin incision was made in the reoperated patients, and there were no problems during follow-up.

Discussion

Orchiopexy is a common treatment procedure in the pediatric population (8). Early treatment of UT is crucial to prevent testicular degeneration, improve fertility, and facilitate the detection of malignancy (9). Traditionally, this procedure is performed through an inguinal procedure with a second incision in the scrotum for the insertion of the testicle. An inguinal incision is essential for adequate mobilization of the undescended testicle and ligation of the hernia sac. Through this incision, the inguinal canal can be easily accessed, cord structures can be identified, and the hernia sac can be dissected and treated with high-ligation. This procedure ensures that the spermatic cord is sufficiently long. A scrotal incision is made for placement

Table 1. Postoperative complications and cosmetic outcomes

		n	%
Hernia Sac	Seen	168	79.2
	Not seen	44	20.8
Undescended testes	Right	112	52.8
	Left	100	47.2
Testicular location in the groin	Location distal to the outer ring	150	70.8
	Placement between the outer and inner rings	62	29.2
Scrotal edema	Seen	8	3.8
	Not seen	204	96.2
Testis atrophy	Seen	0	0
	Not seen	212	100.0
Wound infection	Seen	5	2.4
	Not seen	207	97.6
Testicular protrusion	Seen	3	1.4
	Not seen	209	98.6
Cosmetic satisfaction	Satisfied	208	98.1
	Not satisfied	4	1.9

Table 2. Relationship between Undescended Testis and Testis Position in the Groin with Hernia Sac in Patients Undergoing Scrotal Orchiopexy

	Seen	Hernia Sac				p-Value
		Not seen				
		n				
Undescended testes	Right	111	66.10%	1	2.30%	p<0.001*
	Left	57	33.90%	43	97.70%	
Testicular location in the groin	Location distal to the outer ring	111	66.10%	39	88.60%	p<0.001*
	Placement between the outer and inner rings	57	33.90%	5	11.40%	

* Significant difference at <0.05 level according to Fisher's exact test

of the testes into the dartos pouch and its fixation to the scrotum (10, 11).

PUTs are palpable in the outer inguinal ring or more distal to it. The distance between the outer ring and the upper scrotum is short. Therefore, the idea of performing orchidopexy with a single scrotal incision was proposed. This technique was defined by Bianchi and Squire in 1989 (6). The advantages of this method include a shorter surgical time, less postoperative pain, and fewer scars. The most suitable level for this method is around the outer inguinal ring or when the testes are located in the high scrotal region (6,7). This procedure is less invasive than the standard groin technique. It should be used in undescended testicles located distal to the outer inguinal ring (4, 7). In our study, not only cases distal to the outer inguinal ring but also cases between the outer and inner inguinal rings were included, and this technique was successfully applied.

Hazebroek et al. (12) reported that in most cases of PUT, dissection of the cremaster and processus vaginalis allows sufficient length for the spermatic cord elements. Therefore, the testicles can be placed in the pouch of the dartos without tension. Callewaert et al. (13) suggested that the Bianchi method offers several advantages over the traditional inguinal procedure, owing to its faster operation and better cosmetic outcomes. The Bianchi Method has been shown to be effective in the treatment of primary and secondary cryptorchidism, but the success of this process for inguinal hernias has not been confirmed (6, 13). Redman (14) reported that the lack of widespread use of this technique is due to the complexity of ligation of the hernia sac with a high scrotal incision. However, the importance of ligation of the processus vaginalis in the treatment of UT remains controversial. Parsons et al. (15) reported in their scrotal orchiopexy series that an inguinal incision was necessary for ligation of the patent processus vaginalis, which was found in 20% of cases. On the other hand, several recent clinical studies on scrotal orchiopexy have found that, with traction on the sac, the patent processus vaginalis can be dissected from the cord structures through the inguinal canal (16, 17). In another

study, it was noted that dissection within the canal could be performed solely through externalization without the need to open the anterior wall of the inguinal canal, allowing for ligation and separation of the processus vaginalis, similar to that in inguinal orchiopexy. In our study, 79.2% of patients had a hernia sac. The hernia sacs were ligated through a single high scrotal incision. Excluding the patients who had previously undergone surgery on the same side and the cases in the inner inguinal ring and including the cases with PUT between the outer and inner inguinal ring and distal to the outer inguinal ring may have enabled us to reach this conclusion. However, the fact that all hernia sacs were ligated through a single high scrotal incision and that no inguinal incision was made in any case demonstrates the success of this technique.

In their series of 292 cases, Woong Na et al. (18) reported that the success rate of single scrotal incision orchiopexy was 92.5% and that the hospital stay and operation times were shorter than those for traditional inguinal incision orchiopexy. Bassel et al. (16) reported that the average operation time was less than 20 minutes, and the success rate was 100%. In a similar study, Dayanç et al. (19) reported a success rate of scrotal incision orchidopexy of 94.4% with a short operating time. In our study, the operation time was compatible with the literature, and surgical (98.6%) and cosmetic success (98.1%) were higher. Despite the presence of a hernia sac in 79.2% of cases, it has been observed that the location of the palpable testes does not affect the success rate. In the 20-year transcrotal orchidopexy outcomes reported by Gordon et al. (7), 2.5% of patients required groin incision. In the study of Arena et al. (20), it was observed that 3.9% of cases initially approached transcrotally were converted to the inguinal approach. In our study, no patient underwent a transition to the traditional two-incision procedure.

Re-ascent postoperatively is a very important problem. According to the current literature, it is observed at rates ranging from 1% to 10%. In their study analyzing the effectiveness of inguinal and scrotal approaches in a series of 554 patients who underwent primary orchiopexy, Selin

et al. (21) reported that the re-ascent rate was 7.2% and 3.1%, respectively, and that the surgical approach was not a predictive factor for re-ascent. In our study, the re-ascent rate was 1.4%, which was quite successful, according to the literature. In a series of 100 cases by Nazem et al. (22), scrotal and inguinal orchidopexy for PUT were compared. In their study, no difference was observed between the two methods in terms of testicular hypotrophy, testicular atrophy, wound infection, and relapse rates. The study of Zouari et al. (23) reported that single scrotal-incision orchidopexy in PUT is an effective and reliable method. In the same study, 1% wound dehiscence, 5% scrotal hematoma, and 1% hernia recurrence were observed. In a similar study, Russinko et al. (24) reported an overall success rate of 98.8% and an overall complication rate of 4.7% for prescrotal orchidopexy. Our overall complication rate was also low (7.6%). In a systematic review by Novaes et al. (4), they reported that a single scrotal incision orchiopexy had a high efficacy rate, ranging from 88% to 100%. In our study, very successful results were obtained, including 98.1% cosmetic satisfaction.

Study Limitations

The limitations of this study include its small size, single-center, retrospective design, and short follow-up period. The results of the scrotal orchidopexy technique could not be evaluated using objective parameters. Additionally, the absence of a traditional inguinal orchidopexy group and the lack of a comparative analysis represent another significant limitation. Despite these limitations, our study demonstrates that scrotal orchiopexy is an effective and safe method for treating PUT across a broad age range in childhood.

Conclusion

Scrotal orchidopexy has some advantages; it is easy to learn and master. Minimal dissection and tissue destruction of the groin area. We conclude that this technique is safe and effective and can be an alternative to inguinal orchiopexy in cases in which the PUT is located between the outer and inner inguinal rings and distal to the outer inguinal ring. We would like to state that more prospective, randomized, controlled studies should be conducted to evaluate the efficacy of the scrotal orchiopexy technique.

Ethics

Ethics Committee Approval: The study was approved by the Tokat Gaziosmanpasa University Faculty of Medicine, Clinical Research Ethics Committee (Approval date and number: 18.04.2024/24-KAEK-147).

Informed Consent: While recording patient data, patients were informed that these data would be used for scientific purposes, and written informed consent was obtained from each patient.

Footnotes

Authorship Contributions

Surgical and Medical Practices: K.Y., E.K., F.F., Concept: K.Y., E.K., F.F., Design: K.Y., E.K., F.F., Data Collection or Processing: K.Y., E.K., F.F., Analysis or Interpretation: K.Y., E.K., F.F., Literature Search: K.Y., E.K., F.F., Writing: K.Y., E.K., F.F.

Conflict of Interest: No conflicts of interest were declared by the authors.

Financial Disclosure: This study received no financial support.

References

1. Wahyudi I, Raharja PAR, Situmorang GR, et al. Comparison of scrotal and inguinal orchiopexy for palpable undescended testis: a meta-analysis of randomized controlled trials. *Pediatr Surg Int.* 2024;40:74.
2. Abdelrazek M, Mohammed O, Mahmoud A et al. Laparoscopic versus open orchiopexy in high inguinal undescended testes: A randomized clinical trial. *Int Urol Nephrol.* 2024;56:3511-8.
3. Niedzielski JK, Oszukowska E, Słowikowska-Hilczler J. Undescended testes: current trends and guidelines: a review of the literature. *Arch Med Sci.* 2016;12:667-77.
4. Novaes, H. F., Carneiro, J. A., Macedo, A. Jr., et al. Single scrotal incision orchiopexy: a systematic review. *Int Braz J Urol.* 2013;39(3):305-11.
5. Abbasion R, Mottaghi M, Saeidi Sharifabad P et al. Gubernaculum-sparing orchiopexy versus gubernaculum excision; A randomized trial on success and atrophy rates. *Pediatr Urol.* 2024;20:969-76.
6. Bianchi A, Squire BR. Transcrotal orchidopexy: orchidopexy revised. *Pediatric Surgery International.* 1989;4:189-92.
7. Gordon M, Cervellione RM, Morabito A, Bianchi A. 20 years of transcrotal orchidopexy for undescended testis: results and outcomes. *J Pediatr Urol.* 2010;6:506-12.
8. Dessanti A, Falchetti D, Alberti D et al. Two-stage orchiopexy for intra-abdominal testis with short spermatic vessels wrapped in anti-adhesion conduit. Twenty five years of experience. *J Pediatr Urol.* 2024;20:98-9.
9. Huang W, Xu L, Chen S et al. Evaluation of testicular function changes in unilateral cryptorchid Chinese infants who underwent orchidopexy in the first year of life. *Int Urol Nephrol.* 2024;56: 1537-42.
10. R. Handa, R. Kale, M. Harjai, et al. Single scrotal incision orchiopexy for palpable undescended testis. *Asian J Surg.* 2006;29:25-7.
11. D. Misra, R. Dias, L. Kapila. Scrotal fixation: a different surgical approach for the management of the low undescended testes. *Urology.* 1997;49:762-5.
12. Hazebroek FW, Keizer-Schrama SM, Maarschalkerweerd M et al. Why luteinizing hormone-releasing nasal spray does

- not replace orchidopexy in the treatment of boys with undescended testes. *J Pediatr Surg.* 1987;22:1177-82.
13. Callewaert PRH, Rahnema MS, Bialosterski BT, et al. Scrotal approach to both palpable and impalpable undescended testes: should it become our first choice? *Urology.* 2010;76:73-6.
 14. Redman JF. Simplified technique for scrotal pouch orchiopexy. *Urol Clin North Am.* 1990;17:9-12
 15. Parsons JK, Ferrer F, Docimo SG. The low scrotal approach to the ectopic or ascended testicle. prevalence of patent processus vaginalis. *J Urol.* 2003;169:1832-3.
 16. Bassel YS, Scherz HC, Kirsch AJ. Scrotal incision orchiopexy of undescended testes with or without a patent processus vaginalis. *J Urol.* 2007;177:1516-8.
 17. Yuçel S, Celik O, Kol A, Baykara M, Guntekin E. Initial prescrotal approach for palpable cryptorchid testis: results during a 3-year period. *J Urol.* 2011;185:669-72.
 18. Woong Na S, Kim SO, et al. Single Scrotal Incision Orchiopexy for Children with Palpable Low-Lying Undescended Testis: Early Outcomes of a Prospective Randomized Controlled Study. *Korean J Urol.* 2011;52:637-41.
 19. Dayanç M, Kibar Y, Tahmaz L et al. Scrotal incision orchiopexy for undescended testis. *Urology.* 2004;64:1216-8.
 20. Arena S, Impellizzeri P, Perrone P et al. Experience with Transcrotal Orchidopexy in Children Affected by Palpable Undescended Testis. *Eur J Pediatr Surg.* 2016;26:13-6.
 21. Selin, C., Hallabro, N., Anderberg, M., et al. Orchiopexy for undescended testis—rate and predictors of re-ascent. *Pediatr Surg Int.* 2024;40:139.
 22. Nazem M, Hosseinpour M, Alghazali A. Trans-scrotal Incision Approach versus Traditional Trans-scrotal Incision Orchiopexy in Children with Cryptorchidism: A Randomized Trial Study. *Adv Biomed Res.* 2019;8:34.
 23. Zouari M, Dhaou MB, Jallouli M, et al. Single scrotal-incision orchidopexy for palpable undescended testis in children. *Arab J Urol.* 2014;13:112–5.
 24. Russinko PJ, Siddiq FM, Tackett LD, et al. Prescrotal Orchiopexy: An Alternative Surgical Approach for the Palpable Undescended Testis. *J Urol.* 2003;170:2436-8.