



Retroperitoneal Myelolipoma-related Cushing's Syndrome

Retroperitoneal Miyelolipom İlişkili Cushing Sendromu

Betül Çavuşoğlu, Evrim Çakır*, Süleyman Ahbab, Fatih Türker, Esra Ataoğlu, Mustafa Yenigün

Haseki Training and Research Hospital, Clinic of Internal Medicine, İstanbul, Turkey

*Haseki Training and Research Hospital, Clinic of Endocrinology and Metabolic Diseases, İstanbul, Turkey

Abstract

Myelolipoma (ML) is a benign mesenchymal tumor that can be localized in the adrenal gland and may present as an extraadrenal tumor. Extraadrenal ML can secrete cortisol rarely and cause Cushing's syndrome findings. Radiological imaging (magnetic resonance) is important in identifying extraadrenal masses. Accurate diagnosis can be made by pathological investigation of the biopsy specimen taken from the mass. This case is presented to emphasize ML as a rare cause of Cushing's syndrome.

Keywords: Cushing's syndrome, retroperitoneal, myelolipoma

Öz

Miyelolipom (ML) adrenal ve ekstra-adrenal yerleşimli olabilen mezenkimal benign tümördür. Ekstra-adrenal yerleşimli ML nadiren kortizol salgılayabilir ve Cushing sendromu bulgularına sebep olabilir. Radyolojik görüntüleme ekstra-adrenal kitleyi tespit etmede önemlidir. Kesin tanı kitleden alınan biyopsiy ile konur. Olgumuzda Cushing sendromunun nadir bir sebebi olarak retroperitoneal ekstra-adrenal ML anlatılmıştır.

Anahtar Sözcükler: Cushing sendromu, retroperitoneal, miyelolipom

Introduction

Myelolipoma (ML) is a benign mesenchymal tumor composed of adipose and hematopoietic tissues. ML can be localized in the adrenal gland and may present as an extraadrenal tumor. ML can secrete cortisol rarely and cause the clinical features of Cushing's syndrome (1). In this paper, we present a case of ML as a rare cause of Cushing's syndrome.

Case

A 34-year-old diabetic and hypertensive female patient was admitted to our hospital with the complaints of muscle weakness, fatigue and amenorrhea. She was treated with insulin for diabetes mellitus. There was Cushingoid appearance with truncal obesity, sebaceous moon face, acanthosis nigricans and abdominal striae (Figure 1). Laboratory tests provided the following results: glucose: 170 mg/dL (70-100), urea: 42.3 mg/dL (17-43), creatinine: 0.82 mg/dL (0.51-0.95), erythrocyte sedimentation rate: 35 mm/hour (0-30), hemoglobin A1c:

8.8%, follicle-stimulating hormone: 1.59 mIU/mL (4.54-22.51), luteinizing hormone: 0.31 mIU/mL (12-12.86 mIU/mL), estradiol: 16 pg/mL (49-291), progesterone: 1.75 ng/mL (5.16-18.56), total testosterone: 0.48 pg/mL (0.1-0.75), cortisol: 30.40 ug/dL (6.7-22.6), adrenocorticotrophic hormone (ACTH): <1 pg/mL (7.2-63.3). Eosinopenia, lymphocytopenia and neutrophilia were observed in whole blood cell evaluation. Cortisol level was 27.60 ug/dL after 1 mg dexamethasone suppression test, demonstrating failure of suppression. Pituitary magnetic resonance imaging (MR) was normal. A contrast-enhanced abdominal MR showed multiple lobulated bilateral perirenal masses. The majority of the perirenal masses measuring 5.4 cm in diameter were localized in the right perirenal area (Figure 2). F-18 fluorodeoxyglucose (FDG) positron emission tomography demonstrated increased FDG uptake in the right pararenal area. ML was diagnosed by fine needle biopsy of the perirenal mass. Sepsis, hypoxia and respiratory distress syndrome developed during the treatment and she was

Address for Correspondence/Yazışma Adresi: Betül Çavuşoğlu
Haseki Training and Research Hospital, Clinic of Internal Medicine, İstanbul, Turkey
Phone: : +90 536 366 16 67 E-mail: cavusoglubetul@hotmail.com

Received/Geliş Tarihi: 16 November 2015 **Accepted/Kabul Tarihi:** 23 February 2016
European Congress of Endocrinology 2015, Dublin, Ireland.

©Copyright 2016 by The Medical Bulletin of
Haseki Training and Research Hospital
The Medical Bulletin of Haseki published by Galenos Yayınevi.
©Telif Hakkı 2016 Haseki Eğitim ve Araştırma Hastanesi
Haseki Tıp Bülteni, Galenos Yayınevi tarafından basılmıştır.

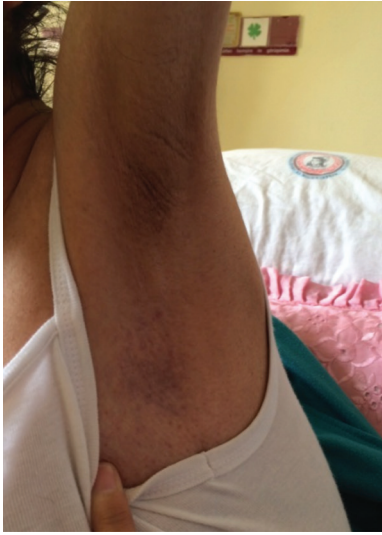

Figure 1. Axillary acanthosis nigricans as a feature of Cushing's syndrome

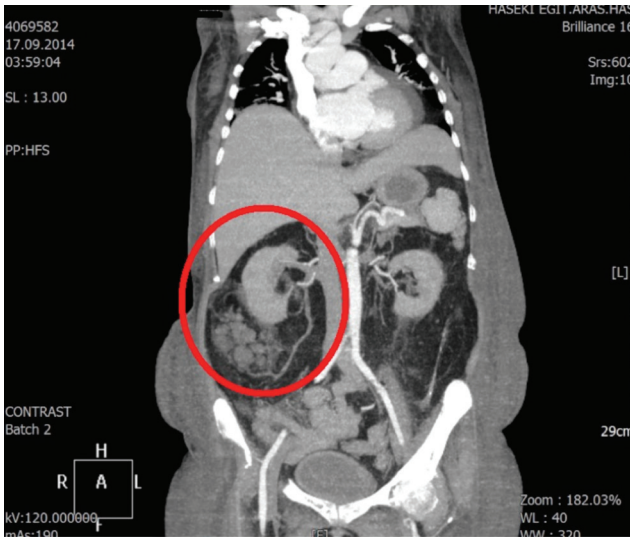


Figure 2. Magnetic resonance imaging shows a retroperitoneal, para-renal lobulated mass

transferred to the intensive care unit. Her clinical status worsened in the intensive care unit and she died after two weeks.

Discussion

Cushing's syndrome is caused by increased levels of cortisol. It has a multifactorial etiology, such as excessive glucocorticoid intake (the most common cause), unilateral or bilateral adrenal hyperplasia, pituitary adenoma (Cushing's disease) and ectopic ACTH or cortisol secretion (2). Patients present with trunk obesity, sebaceous moon

face, hirsutism, muscle wasting, insulin resistance, glucose intolerance, dyslipidemia, thin extremities, decreased bone density, amenorrhea, high blood pressure, and abdominal striae. Our patient had all these clinical features and the laboratory tests revealed a high cortisol level, which demonstrates failure of suppression in dexamethasone suppression test. Serum ACTH level can distinguish whether Cushing's syndrome is due to an ACTH-dependent or independent cause. The ACTH level in our patient was 1 pg/mL, demonstrating ACTH-independence. MLs usually do not secrete hormones, such that only 10% of them cause endocrine disorders, such as Cushing's syndrome, congenital adrenal hyperplasia, Conn's syndrome, pheochromocytoma, hyperparathyroidism and adrenogenital syndrome (3). In our case, the extra-adrenal perirenal ML secreted cortisol, leading to Cushing's syndrome. In an autopsy series according to the archives of the Armed Forces Institute of Pathology between 1981 and 1997, only 10 out of 67 cases were extra-adrenal (4). Cases of adrenal ML associated with Cushing's syndrome have also been reported previously. However, this is the first case of an extra-adrenal perirenal ML associated with Cushing's syndrome in the literature.

Ethics

Informed Consent: Consent form was filled out by all participants.

Peer-review: Internally peer-reviewed.

Authorship Contributions

Concept: Betül Çavuşoğlu. **Design:** Evrim Çakır. **Data Collection or Processing:** Evrim Çakır, Süleyman Ahabab. **Analysis or Interpretation:** Betül Çavuşoğlu, Esra Ataoğlu. **Literature Search:** Fatih Türker, Mustafa Yenigün. **Writing:** Betül Çavuşoğlu, Evrim Çakır.

Conflict of Interest: No conflict of interest was declared by the authors.

Financial Disclosure: The authors declared that this study received no financial support.

References

1. Franiel T, Fleischer B, Raab BW, et al. Bilateral thoracic extraadrenal myelolipoma. *Eur J Cardiothorac Surg* 2004;26:1220-2.
2. Hakim A, Rozeik C. Adrenal and extra-adrenal myelolipomas - a comparative case report. *J Radiol Case Rep* 2014;8:1-12.
3. Rao P, Kenney PJ, Wagner BJ, et al. Imaging and pathologic features of myelolipoma. *Radiographics* 1997;17:1373-85.
4. Goldman S, Kenney P. The adrenal gland. In: LEE J, editor. *Computed body tomography with MRI correlation*. 4th ed. Philadelphia: Lippincott Williams & Wilkins; 2006. p. 1311-73.