



# Localization Features of Loose Bodies in Secondary Synovial Chondromatosis of the Knee Joint

## *Diz Ekleminin Sekonder Sinoviyal Kondromatozisinde Serbest Cisimciklerin Yerleşim Özellikleri*

Çiğdem Özkara Bilgili, Tuba Selçuk\*, Fuat Bilgili\*\*, Hafize Otcu\*, Ferhat Çengel\*, Nurdan Göçgün\*

Bayrampaşa State Hospital, Clinic of Radiology, İstanbul, Turkey

\*Haseki Training and Research Hospital, Clinic of Radiology, İstanbul, Turkey

\*\*İstanbul University Faculty of Medicine, Department of Orthopedics and Traumatology, İstanbul, Turkey

### Abstract

**Aim:** To investigate the relationship of cartilage loss in tibiofemoral and patellofemoral joints with the number, size and location of loose bodies in secondary synovial chondromatosis (SC).

**Methods:** Eighty-eight patients with secondary SC were evaluated retrospectively. The size and location of loose bodies were evaluated by both X-ray and magnetic resonance imaging. The relationship between cartilage lesions and the number, location and size of loose bodies were assessed by Chi-square test and Fisher's exact test.

**Results:** When the relationship between the presence of loose body and cartilage damage was evaluated, it was observed that 83% of subjects (n=74) had cartilage loss at the tibiofemoral joint, 75% (n=66) on the medial and 9% (n=8) of patients had on the lateral side. It was determined that when the number of loose bodies was  $\leq 5$ , the mean diameter was 7.3 mm (2-21 mm). It was 12.7 mm (2-30 mm) when the number was  $>5$ . The most frequently affected locations were the posterior compartment of the posterior cruciate ligament and the superior compartment of the popliteal fossa, regardless of the degree of cartilage loss.

**Conclusion:** We concluded that the higher the cartilage damage, the higher the number and size of loose bodies. We assume that our study provides insight into further investigations to study new classification system for secondary SC in the knee joint.

**Keywords:** Synovial chondromatosis, magnetic resonance imaging, secondary, knee joint

### Öz

**Amaç:** Sekonder sinoviyal kondromatoziste (SK) tibiofemoral ve patellofemoral eklemlerde kıkırdak kaybının serbest cisimciklerin sayı, boyut ve yerleşim yerlerinin ilişkilerinin değerlendirilmesi.

**Yöntemler:** Sekonder SK olan seksen sekiz hastanın direkt grafi ve manyetik rezonans görüntüleme (MRG) tetkikleri retrospektif olarak değerlendirildi. Serbest cisimciklerin boyut ve yerleşim yerleri hem direkt grafi hem de MRG incelendi. Tibiofemoral ve patellofemoral eklemlerdeki kıkırdak lezyonlarının serbest cisimciklerin sayı, yerleşim yeri ve boyutları arasındaki ilişki Chi-square ve Fisher'in exact testleri ile değerlendirildi.

**Bulgular:** Serbest cisimciklerin ve kıkırdak hasarının varlığı arasındaki ilişki değerlendirildiğinde olguların %83'ünde (n=74) tibiofemoral eklemden %75'i (n=66) medyalde %9'u (n=8) lateralde olmak üzere kıkırdak kaybı olduğu saptandı. Serbest cisimciklerin sayısı  $\leq 5$  olduğunda ortalama çaplarının 7,3 mm (2-21 mm), sayı  $>5$  olduğunda ise 12,7 mm (2-30 mm) olduğu saptandı. En sık yerleşim yerlerinin ise kıkırdak hasarından bağımsız olarak arka çapraz bağ posterioru ve popliteal fossa olduğu görüldü.

**Sonuç:** Sekonder SK kıkırdak hasarı arttıkça serbest cisimciklerin de sayı ve boyutlarında artış olduğu sonucuna ulaştık. Çalışmamız dizde sekonder SK ile ilgili ileride yapılacak sınıflama sistemlerine fikir vereceği kanısındayız.

**Anahtar Sözcükler:** Sinoviyal kondromatozis, manyetik rezonans görüntüleme, sekonder, diz eklemleri

## Introduction

Synovial chondromatosis (SC) is a benign condition which develops as a result of multiple chondral foci formation in the synovium due to metaplasia of mesothelial or submesothelial layer of the bursal synovial membrane or joint tendon sheaths. Primary or idiopathic SC is a rare condition in which calcified lesions typically occur in the joint due to synovial metaplasia. On the other hand, secondary SC may develop as a consequence of other joint diseases such as degenerative joint disease, osteochondritis dissecans, neurotrophic arthritis, tuberculosis arthritis and osteochondral fractures. It is mostly seen between 40 and 60 years of age. Those chondral foci are detached from the synovium and form intra-articular loose bodies. These loose bodies are less in number when compared to primary SC and may vary in size. Secondary type is mostly seen together with osteoarthritis of the knee. It has been suggested that it occurs as a result of joint surface fragmentation, detachment of osteophytes, or osteochondral nodule proliferation in the periarticular soft tissue (1-3). Histologically, SC shows three types as chondral, osteochondral and osseous (4). Another classification based on magnetic resonance imaging (MRI) findings is present for primary SC but not for secondary SC (5). In the literature, there is no previous study investigating the relationship between osteoarthritis and SC. In this study, we aimed to investigate the relationship of cartilage loss in the tibiofemoral and patellofemoral joints with the number, size and location of loose bodies in secondary SC. We hypothesized that the more loss of cartilage in the knee joint, the higher number and size of loose bodies.

## Methods

### Patient Population

4200 patients, who underwent X-ray and MRI of the knee joint with suspected chondropathy between January 2012 and December 2013, were evaluated retrospectively for the presence of SC.

Patients over 40 years of age were included in our study considering the higher incidence of having secondary osteoarthritis in this age group. Other inclusion criteria were presence of intraarticular calcified loose bodies with different sizes detected on lateral knee X-ray and on MRI.

Patients below 40 years of age and with a history of previous knee surgery were not included in the study. Additionally, patients having uniform size of loose bodies in their joints were excluded.

A total of eighty-eight patients (50 women and 38 men) who met those criteria were included in this study.

### Scan Protocol

We used a 1.5 Tesla (T) MRI scanner (Philips Achieva, Best, the Netherlands). Four millimeter (mm) slice thickness with 1 mm gap in T1-weighted (T1W) sagittal (TE=20, TR=800 m/sec), proton density (PD)-weighted axial, coronal and sagittal images were acquired (TE=30, TR=1500 m/sec).

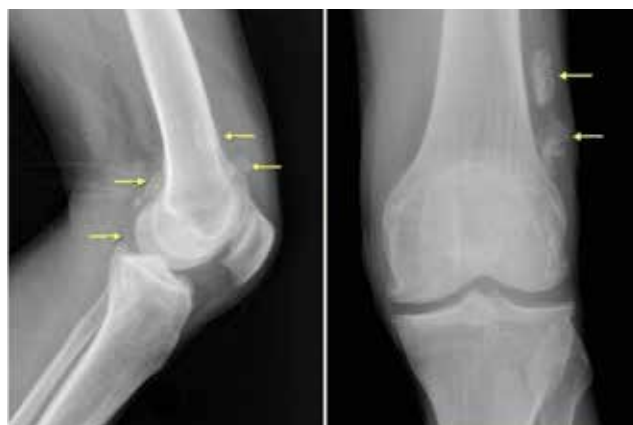## Image Analysis

For analysis, image data sets were transferred to a PACS system (Infinit HealthCare, Seoul, South Korea). Both X-ray and MRI images of the patients were evaluated retrospectively by two experienced musculoskeletal radiologist (5-7 years of experience). Lateral X-ray images were evaluated according to the presence of juxtaarticular radioopaque nodules with various sizes (Figure 1).

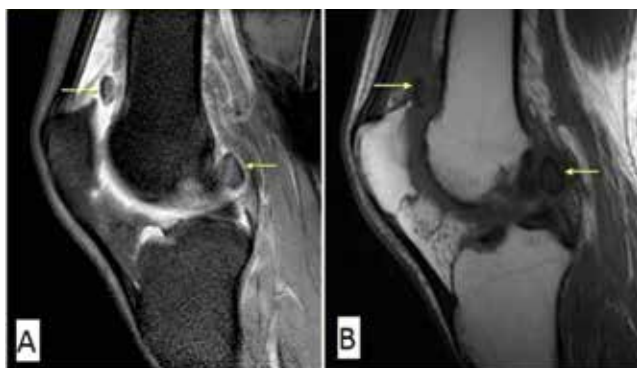On MRI, the signal properties vary due to their tissue content and depend on the degree of synovial proliferation and nodule calcification-ossification. Chondral SC; the most common type, shows T1W hypointensity and T2W hyperintensity on MRI, whereas the calcified nodules show hypointensity both on T1W and T2W images. Then, the number, size and location of loose bodies were evaluated on MRI images of these patients (Figure 2A, 2B).

According to the number of loose bodies, we classified as equal and/or less than 5 ( $\leq 5$ ) and more than 5 ( $> 5$ ). Size of these loose bodies were divided into two subgroups also as  $\leq 5$  mm and  $> 5$  mm. The location was reported as posterior to the posterior cruciate ligament (PCL), superior to the popliteal fossa, intercondylar notch, suprapatellar bursa and disseminated (Figure 3A-3D).

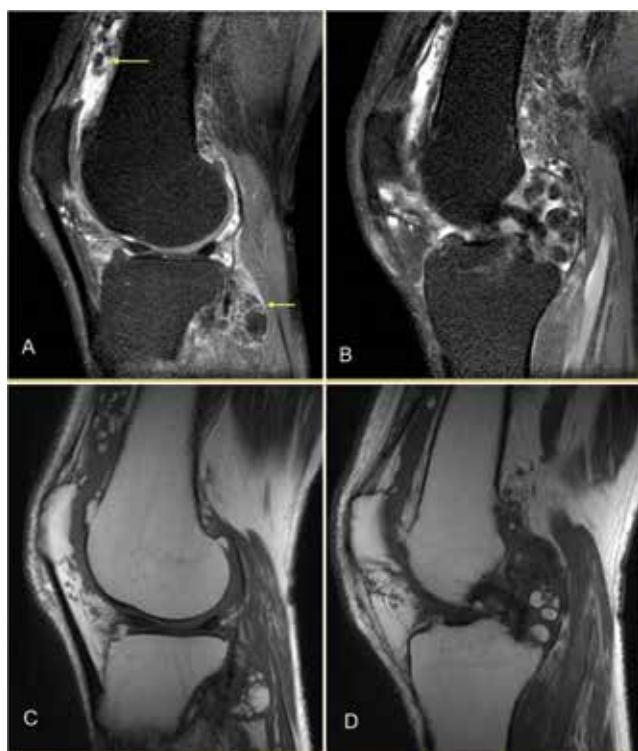
The relationship between the number of loose bodies and their location was evaluated. In addition, cartilage damage was evaluated based on the modified Outerbridge classification (6). According to this classification, study group was divided into two subgroups based on the presence or absence of cartilage damage. The group with cartilage damage further was divided into two groups according to the degree of involvement as cartilage loss  $\leq 50\%$  and  $> 50\%$  (Figure 4). Cartilage loss was evaluated on coronal short tau inversion recovery (STIR) MR images for the tibiofemoral joint. The correlation between the number of loose bodies and cartilage damage was noted further.



**Figure 1.** Knee X-rays show suprapatellar and intraarticular osteochondral bodies of different sizes and shapes (arrows). The largest osteochondral fragment uppermost in the suprapatellar region reveals two rings of calcification; these features are typical of secondary chondromatosis



**Figure 2.** Sagittal proton density weighted (A) and T1-weighted (B) magnetic resonance imaging image demonstrates numerous calcified loose bodies in knee joint consistent with synovial chondromatosis



**Figure 3.** Sagittal proton-density-weighted (A, B) and T1-weighted (C, D) magnetic resonance imaging images reveal the extensive diffuse synovial process with osteochondral bodies

### Statistical Analysis

Statistical analysis was performed using Predictive Analytics Software (PASW) Statistics 17.0 (SPSS Inc., Chicago, IL, USA). Quantitative variables were determined as mean (range) values while categorical variables were expressed as frequency or percentages. The relationship of meniscal and cartilage lesions with the number, location and size of loose bodies were assessed by Chi-square test and Fisher's exact test.

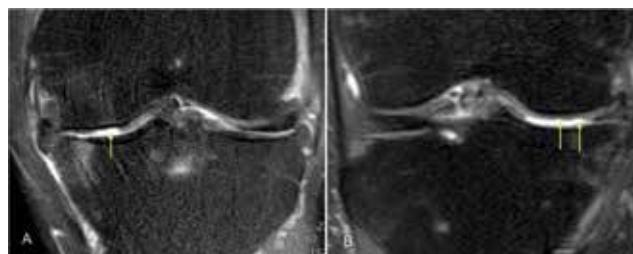
### Results

The mean age of the patients was 51 (range: 39-66) years. All patients had loose bodies in their knee joints as a part of secondary SC. The number of loose bodies was  $\leq 5$  in 66 patients (75%) and more than 5 in 22 (25%) patients. When the relationship between the number and the sizes of loose bodies were evaluated, it was determined that when the number is  $\leq 5$ , the mean diameter was 7.3 mm (2-21 mm), whereas it was 12.7 mm (2-30 mm) when the number is more than 5.

The incidence of involved compartments was not different between the groups with the number of loose bodies  $\leq 5$  and  $>5$  (Table 1).

When the relationship between the presence of loose body and cartilage damage was evaluated, 83% of cases (n=74) was shown to have cartilage loss in the tibiofemoral joint (TFJ), 75% (n=66) on the medial (Table 2) and 9% (n=8) on the lateral side.

Loss of cartilage in the patellofemoral joint was observed in 38 (43.1%) subjects. This correlation was statistically significant only in medial TFJ ( $p < 0.05$ ). In these 66 patients, the relationship between the number of the



**Figure 4.** Proton density-weighted coronal magnetic resonance imaging image shows a partial and full thickness cartilage defect over the medial femoral condyle (arrows)

**Table 1. Comparison of the affected compartments in terms of loose body number**

Compartments	Loose body number $\leq 5$ (n)	Loose body number $>5$ (n)
Posterior cruciate ligament posterior	44	21
Knee joint posterior-superior (popliteal fossa)	24	20
Intercondylar notch	17	19
Suprapatellar bursa	12	19
All compartments	3	12

loose bodies and the degree of the cartilage loss was evaluated and a significant linear correlation was detected ( $p<0.05$ ) (Table 3) (Graphic 1).

All compartments were affected to some extent. When the relationship between the involved compartments and the amount of the cartilage loss was evaluated, it was seen that the more the cartilage loss the more the number of affected compartments. And the most frequently affected locations were compartments posterior to the PCL and superior to the popliteal fossa regardless of the degree of the cartilage loss (Table 4).

### Discussion

SC develops as a result of cartilaginous metaplasia of the synovial membrane. All joints may be affected, but the most common location is the knee joint (3). It may develop primarily as a result of chondroid foci formation from the synovial membrane which is seen mostly at 20-40 years of age in primary SC (2,7). On the other hand, secondary SC occurs as a result of some diseases such as osteoarthritis dissecans, osteocartilaginous fractures, and neuropathic arthropathy (1-3). It is seen in elderly people aged between 40 and 60 years as in our study. Distinguishing between these two types is important in guiding the treatment. According to Milgram's classification, in stage II primary SC, synovectomy should be added to removal of the loose body as synovial involvement is present (8-10). On

the other hand, the treatment of secondary SC focuses on cartilage or meniscus lesions which are the sources of loose bodies (2,11).

The number of loose bodies provides information on disease etiology. Solitary SC develops as a result of cartilage or meniscus lesions due to trauma (12). The number and size of these loose bodies increase by initiation of degenerative process. Normally, the number of loose bodies in primary SC is higher than 5. In secondary SC, the number of loose bodies is not as much as that in primary SC. Besides, they do not tend to be uniform as in primary SC (13). In the literature, there are reported cases of giant solitary SC. It has been suggested that these bodies may arise from the synovial membrane or through mergence of smaller loose bodies (12,14,15). As this occurs in time, it may suggest that degenerative process has been continuing for a long time. In our study, a linear correlation was found between the number of loose bodies and as well as amount of cartilage loss. And this cartilage loss was seen to be more prominent in the medial tibiofemoral joint. This result affirms the relationship of secondary SC with osteoarthritis which is a disease of aging cartilage.

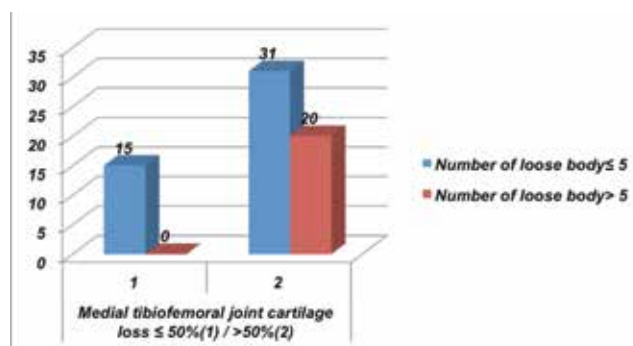
SC mostly occurs in the knee joint (3). Its localization differs according to its type. The localization of primary SC in the knee joint is mostly the anterior compartment (2,16). A limited number of patients with posterior compartment localization have also been reported (17-19). In our study, contrary to primary SC, patients with secondary SC showed mostly posterior compartment involvement regardless of the number of the loose bodies. In both groups the most common location was the compartment posterior to PCL

**Table 2. The relation between the number of loose bodies and the presence of cartilage loss in medial tibiofemoral joint**

Number of loose body (n)	Cartilage loss (+)	Cartilage loss (-)
n≤5	46	20
n>5	20	2
Total	66	22

**Table 3. The relation between the degree of the cartilage loss in medial tibiofemoral joint and the number of loose bodies**

Loose body number (n)	Cartilage loss ≤50%	Cartilage loss >50%
n≤5	15	31
n>5	0	20
Total	15	51



**Graphic 1.** The correlation between the degree of the cartilage loss in medial tibiofemoral joint and the number of loose bodies

**Table 4. The relation between the degree of cartilage loss and the involved compartments in terms of presence of loose bodies**

Compartments	Cartilage loss ≤50% (n)	Cartilage loss >50% (n)	Total (n)
Posterior cruciate ligament posterior	10	42	52
Popliteal fossa superior	4	31	35
Intercondylar notch	2	25	27
Suprapatellar bursa	1	24	25
Disseminated	0	17	17

followed by that superior to popliteal fossa. In our study, it was also determined that there was a linear correlation between the number of loose bodies and the widespread nature of the disease in the knee joint.

Finally, when the presence of accompanying meniscal tear was evaluated, we concluded that because secondary SC develops mainly as a result of degenerative process, degenerative changes of the tibiofemoral joints usually accompany and, as being part of this process, meniscal tears are also seen together.

The imitations of our study were its retrospective design, lack of arthroscopic diagnosis and pathological examination of the loose bodies. However, we have mostly overcome these problems by including patients with osseous loose bodies which may be specifically diagnosed radiologically. Radiologic criteria in differential diagnosis (presence on X-ray, lesser number and smaller size of loose bodies), along with occurrence in the elderly population strengthen the diagnosis.

## Conclusion

Secondary SC develops as a result of other joint diseases. When the loose bodies in SC are less in number, they lead to progression of osteoarthritis by a mechanical effect which may cause an increase in the diameter and amount of loose bodies ending up in a vicious cycle. In our study, we evaluated the presence and number of loose bodies in secondary SC in relation to cartilage loss. Also, we pointed out their frequent locations. In primary SC, the most common localization for loose bodies is the anterior compartment. However, in our study, the most common localization was the posterior compartment. This result is important in differentiating the primary versus secondary SC which is important because of different clinical outcomes and treatment approaches. Also, we concluded that the higher the cartilage damage, the higher the number and size of loose bodies. We assume that our study provides insight into further investigations to study new classification system for secondary SC in the knee joint.

## Acknowledgements

Thank to Kamber Kasali for statistical assistance.

## Author Contributions

*Ethics Committee Approval: No ethics committee approval, Informed Consent: Consent form was filled out by all participants, Concept: Çiğdem Özkara Bilgili, Tuba Selçuk, Design: Çiğdem Özkara Bilgili, Fuat Bilgili, Data Collection or Processing: Çiğdem Özkara Bilgili, Ferhat Çengel, Analysis or Interpretation: Çiğdem Özkara Bilgili, Hafize Otçu, Literature Search: Çiğdem Özkara Bilgili, Nurdan Göçgün, Writing: Çiğdem Özkara Bilgili, Tuba Selçuk, Fuat Bilgili, Peer-review: External and Internal peer-reviewed, Conflict of Interest: No conflict of interest was declared by the authors, Financial Disclosure: The authors declared that this study has received no financial support.*

## References

- Milgram JW. The classification of loose bodies in human joints. *Clin Orthop Relat Res* 1977;282-91.
- Kyung BS, Lee SH, Han SB, Park JH, Kim CH, Lee DH. Arthroscopic treatment of synovial chondromatosis at the knee posterior septum using a trans-septal approach: report of two cases. *Knee* 2012;19:732-5.
- Maurice H, Crone M, Watt I. Synovial chondromatosis. *J Bone Joint Surg Br* 1988;70:807-11.
- Saotome K, Tamai K, Osada D, Oshima F, Koguchi Y, Hoshikawa A. Histologic classification of loose bodies in osteoarthritis. *J Orthop Sci* 2006;11:607-13.
- Kramer J, Recht M, Deely DM, et al. MR appearance of idiopathic synovial osteochondromatosis. *J Comp Assist Tomogr* 1993;17:772-6.
- Sanders TG, Paruchuri NB, Zlatkin MB. MRI of osteochondral defects of the lateral femoral condyle: incidence and pattern of injury after transient lateral dislocation of the patella. *Am J Roentgenol* 2006;187:1332-7.
- Villacin AB, Brigham LN, Bullough PG. Primary and secondary synovial chondrometaplasia: histopathologic and clinicoradiologic differences. *Hum Pathol* 1979;10:439-51.
- Milgram JW. Synovial osteochondromatosis: a histopathological study of thirty cases. *J Bone Joint Surg Am* 1977;59:792-801.
- Ackerman D, Lett P, Galat DD Jr, Parvizi J, Stuart MJ. Results of total hip and total knee arthroplasties in patients with synovial chondromatosis. *J Arthroplasty* 2008;23:395-400.
- Chapter in Temple HT, Gibbons CL. Tumors and tumor-related conditions about the knee. In: Bulstrode C, Buckwalter J, Carr A, et al, Editors. *Oxford Textbook of Orthopaedics and Trauma* Oxford: Oxford University Press; 2002:1153-4.
- Dorfmann H, De Bie B, Bonvarlet JP, Boyer T. Arthroscopic treatment of synovial chondromatosis of the knee. *Arthroscopy* 1989;5:48-51.
- Ogilvie-Harris DJ, Saleh K. Generalized synovial chondromatosis of the knee: a comparison of removal of the loose bodies alone with arthroscopic synovectomy. *Arthroscopy* 1994;10:166-70.
- McKenzie G, Raby N, Ritchie D. A pictorial review of primary synovial osteochondromatosis. *Eur Radiol* 2008;18:2662-9.
- Edeiken J, Edeiken BS, Ayala AG, Raymond AK, Murray JA, Guo SQ. Giant solitary synovial chondromatosis. *Skeletal Radiol* 1994;23:23-9.
- Sourlas I, Brilakis E, Mavrogenis A, Stavropoulos N, Korres D. Giant intra-articular synovial osteochondromata of the knee. *Hippokratia* 2013;17:281-3.
- Bozkurt M, Uğurlu M, Doğan M, Tosun N. Synovial chondromatosis of four compartments of the knee: medial and lateral tibiofemoral spaces, patellofemoral joint and proximal tibiofibular joint. *Knee Surg Sports Traumatol Arthrosc* 2007;15:753-5.
- Church JS, Bredahl WH, Janes GC. Recurrent synovial chondromatosis of the knee after radical synovectomy and arthrodesis. *J Bone Joint Surg Br* 2006;88:673-5.
- Jesalpara JP, Chung HW, Patnaik S, Choi HW, Kim JI, Nha KW. Arthroscopic treatment of localized synovial chondromatosis of the posterior knee joint. *Orthopedics* 2010;33:49.
- Pengatteeeri Y, Park SE, Lee HK, Lee YS, Gopinathan P, Han CW. Synovial chondromatosis of the posterior cruciate ligament managed by a posterior-posterior triangulation technique. *Knee Surg Sports Traumatol Arthrosc* 2007;15:1121-4.