

A Case of Goldenhar's Syndrome and Intracardiac Aneurysm

Goldenhar Sendromu ve Intrakardiyak Anevrizması Olan Bir Olgu

Ali Karaman, Fuat Laloğlu*, Hasan Kahveci*

Erzurum Nenehatun Obstetrics and Gynecology Hospital, Clinic of Medical Genetics, Erzurum, Turkey

*Erzurum Nenehatun Obstetrics and Gynecology Hospital, Neonatal Intensive Care Unit, Erzurum, Turkey

Abstract

Goldenhar's syndrome is a rare variant of oculo-auriculo-vertebral dysplasia characterized with ear, cardiac, and vertebral anomalies, facial asymmetria and mandibular hypoplasia. The etiology of Goldenhar's syndrome still remains unclear. Here we report a case of a 5 day old female with Goldenhar's syndrome and intracardiac aneurysm. (*The Medical Bulletin of Haseki 2011; 49: 90-2*)

Key Words: Goldenhar's syndrome, microtia, intracardiac aneurysm

Özet

Goldenhar sendromu kulak, kalp ve vertebra anomalileri, fasiyal asimetri ve mandibula hipoplazisi ile karakterize okülo-aurikulo-vertebral displazinin nadir bir varyantıdır. Goldenhar sendromunun etyolojisi hala belirsizliğini korumaktadır. Burada, intrakardiyak anevrizması ve Goldenhar sendromu olan 5 günlük dişi bir olguyu sunduk. (*Haseki Tıp Bülteni 2011; 49: 90-2*)

Anahtar Kelimeler: Goldenhar sendromu, mikrotiya, intrakardiyak anevrizma

Introduction

Goldenhar's syndrome [(oculo-auriculo-vertebral syndrome (OAVS))] is a congenital condition characterized by various anomalies classically involving the face, eyes, and ears. This disorder was first described by Dr. Maurice Goldenhar in 1952 (1). Later, in 1963, Gorlin et al. named it as oculo-auriculo-vertebral syndrome (2). The incidence of OAVS has been estimated to be 1:3500-1:5600 live births, with a male:female ratio of 3:2 (3). Familial history suggesting an autosomal recessive and dominant pattern of inheritance has been reported. However, the majority of the OAVS cases are sporadic and without a known etiology (4-6). Here, we report a newborn with Goldenhar's syndrome and intracardiac aneurysm.

Case Report

The patient, a 5-day-old female infant, was the second child of nonconsanguineous young parents: the mother was 29 and the father was 34 years old. The first child was healthy. Delivery was uneventful; birth weight was 2700 g,

length 49 cm, and occipitofrontal head circumference 35 cm. Physical examination revealed bilateral dysplasia of the external ears and bilateral preauricular skin tags (Figure 1). The child developed severe respiratory distress and was transferred to the neonatal intensive care unit. Ultrasound of the cranium and abdomen were normal and x-ray of the spine showed normal vertebra. Left interatrial septal aneurysm was detected on echocardiography (Figure 2). Karyotyping of lymphocytes from peripheral blood with GTG banding was normal (46,XX). Ophthalmological assessment was normal. The child progressed with ongoing improvement to the respiratory condition. She is currently followed up, receiving medical treatment and awaiting heart surgery.

Discussion

Goldenhar's syndrome (oculo-auriculo-vertebral spectrum) is a condition featuring the following triad of anomalies: ocular anomalies, otic anomalies, and vertebral anomalies (7,8). Multiple malformations, including congenital heart disease, have also been reported (9).

Address for Correspondence/Yazışma Adresi: Ali Karaman
Erzurum Nenehatun Obstetrics and Gynecology Hospital,
Department of Medical Genetics, Erzurum, Türkiye
Tel.: +90 442 317 22 95 Fax.: +90 442 317 22 94 E-posta: alikaramandr@hotmail.com
Received/Geliş Tarihi: 08 Ekim 2010 **Kabul Tarihi/Accepted:** 26 Aralık 2010

Haseki Tıp Bülteni,
Galenos Yayınevi tarafından basılmıştır. Her hakkı saklıdır.
The Medical Bulletin of Haseki Training and Research Hospital,
published by Galenos Publishing. All rights reserved.

The etiology of Goldenhar's syndrome is itself related to vascular disruption, particularly of branches of the internal and external carotid arteries, which leads to morphogenetic alterations in the structures derived from the first and second branchial arches of the first pharyngeal pouch, the first branchial cleft, and the primordial of the temporal bone (10,11,12). In addition, studies with animal models have suggested that Goldenhar's syndrome occurs due to a vascular disruption in the embryo, at 35 to 40 days gestation (8,13).

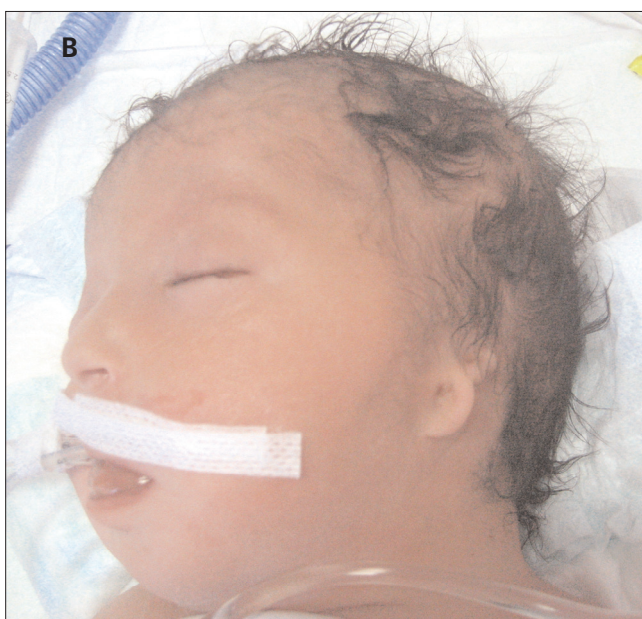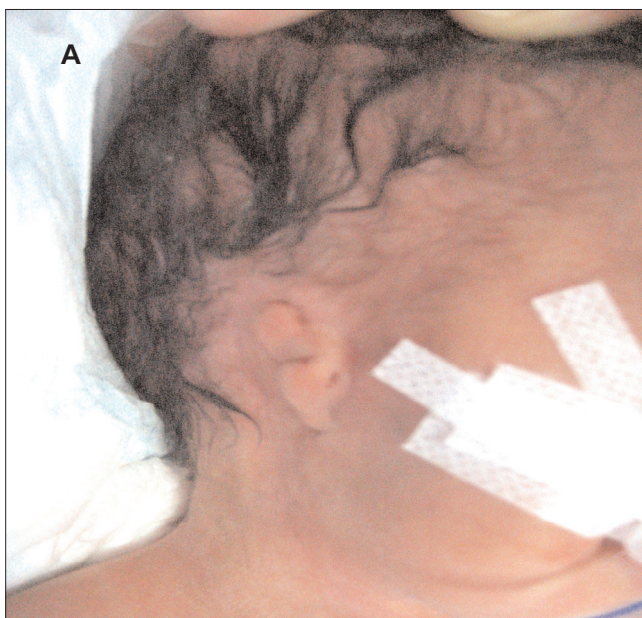


Figure 1. Patient with Goldenhar's syndrome: Bilateral dysplasia of the external ears, bilateral preauricular skin tags (A,B)

Affected individual may have unilateral microphthalmia, and upper eyelid coloboma, hypoplastic jaw, hypoplasia of the facial musculature, microtia, low set ears, preauricular tags, pretragal blind-ended fistulas, dysplasia of the external ear, hemivertebra or hypoplasia of cervical, thoracic or lumbar vertebrae, epibulbar dermoids or lipodermoids, cleft lip and/or palate as well as cardiac, renal and central nervous system anomalies (3,8,14). In some cases, the development of specific features and the severity of the clinical presentation were related to cerebral alterations frequently described in the literature (15,16).

In this paper, we report an unusual coincidence of Goldenhar's syndrome and intracardiac aneurysm that has not been described previously. The patient had bilateral dysplasia of the external ears and bilateral preauricular skin tags. The echocardiogram revealed left interatrial septal aneurysm. The child developed severe respiratory distress and was transferred to the neonatal intensive care unit. Ultrasound of the cranium and abdomen were normal and x-rays of the spine showed normal vertebra.

The real frequency of cardiovascular malformations in subjects with of Goldenhar's syndrome is unknown due to the different results published in the literature (5% to 58%) (17,18). Previous reports have described congenital heart diseases, and tetralogy of Fallot was the most commonly encountered cardiac malformation affecting 6 out of 13 infants with Goldenhar's syndrome (19)

Since the majority of Goldenhar's syndrome cases are sporadic, the risk of recurrence is low, although some authors have reported empirical risk of up to 6% for first degree relatives of affected children. To our knowledge this is the first report of a coincidence of intracardiac aneurysm and Goldenhar's syndrome.

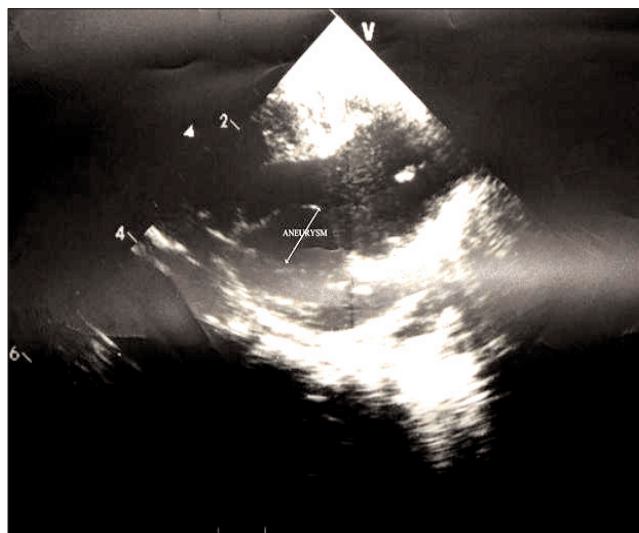


Figure 2. The echocardiogram image of the patient with Goldenhar's syndrome: The arrow show the left interatrial septal aneurysm

References

1. Goldenhar M. Associations malformatives de l'oeil et de l'oreille, en particulier le syndrome epibulbaire-appendices auriculaires dermoide fistula auris congenita et ses relations avec la dysostose mandibulo faciale. *J Genet Hum* 1952;1:243-82.
2. Gorlin RJ, Pindborg JJ. Oculoauriculo-Vertebral Dysplasia. In: *Syndromes of The Head and Neck*. New York: McGraw-Hill; 1964. p. 546-52.
3. Grabb WC. The first and second brachial arch syndromes. *Plast Reconstr Surg* 1965;36:485-508.
4. Castori M, Brancati F, Rinaldi R et al. Antenatal presentation of the oculo-auriculo-vertebral spectrum (OAVS). *Am J Med Genet* 2006;140:1573-79.
5. Cohen MM Jr, Rollnick BR, Kaye CI. Oculoauriculovertbral spectrum: an up dated critique. *Cleft Palate J* 1989;26:276-86.
6. Stromland K, Miller M, Sjögren L, Johansson M, Joelsson BME, Billstedt E. Oculo-auriculo-vertebral spectrum: associated anomalies, functional deficits and possible developmental risk factors. *Am J Med Genet* 2007;143:1317-25.
7. Hunt JA, Hobar PC. Common craniofacial anomalies: the facial dysostoses. *Plast Reconstr Surg* 2002;110:1714-25.
8. Gorlin RL. Branchial Arch and Oro-acral Disorders. In: *Syndromes of The Head and Neck*. Gorlin JJ, Cohen Jr MM, Hennekam RC (ed). London: Oxford University Press; 2001. p. 790-97.
9. Pierpont MEM, Moller JH, Gorlin RJ et al. Congenital cardiac, pulmonary, and vascular malformations in oculoauriculovertbral dysplasia. *Pediatr Cardiol* 1982;2:297-302.
10. Burck U. Genetic aspects of hemifacial microsomia. *Hum Genet* 1983;64:291-96.
11. Jones KL. Oculo-Auriculo-Vertebral Spectrum. In: *Smith's Recognizable Patterns of Human Malformation*. 6th ed. Philadelphia: Elsevier Saunders; 2006. p. 738-41.
12. Kokavec R. Goldenhar's syndrome with various clinical manifestations. *Cleft Palate Craniofac J* 2006;43:628-34.
13. Soltan HC, Holmes LB. Familial occurrence of malformations possibly attributable to vascular abnormalities. *J Pediatr* 1986;108:112-14.
14. Schrandt-Stumpel CT, de Die-Smuiders CE, et al. Oculo-auriculo-vertebral spectrum and cerebral anomalies. *J Med Genet* 1992;29:326-31.
15. Tasse C, Böhringer S, Fischer S, et al. Oculo-auriculo-vertebral spectrum (OAVS): clinical evaluation and severity scoring of 53 patients and proposal for a new classification. *Eur J Med Genet* 2005;48:397-411.
16. Greenwood RD, Rosenthal A, Sommer A, et al Cardiovascular malformations in oculoauriculovertbral dysplasia (Goldenhar syndrome). *J Pediatr* 1974;85:816-8.
17. Kumar A, Friedman JM, Taylor GP, et al. Pattern of cardiac malformation in oculoauriculovertbral spectrum. *Am J Med Genet* 1993;46:423-6.
18. Rollnick BR, Kaye CI, Nagatoshi K, et al. Oculoauriculovertbral dysplasia and variants: Phenotypic characteristics of 294 patients. *Am J Med Genet* 1987;26:361-75.
19. Greenwood RD, Rosenthal A, Sommer A, et al. Cardiovascular malformations in oculoauriculovertbral dysplasia (Goldenhar syndrome). *J Pediatr* 1974;85:816-18.