

# Recurrent Gastrointestinal Bleeding in a Patient with Eisenmenger's Syndrome Secondary to Atrial Septal Defect: A Case Report and Review of the Literature

## *Atriyal Septal Defekte Bağlı Eisenmenger Sendromlu Hastada Tekrarlayan Gastrointestinal Kanama: Bir Olgu Sunumu ve Literatür Değerlendirmesi*

Hüseyin Gündüz, Altuğ Ösken , Mehmet Bülent Vatan, İbrahim Kocayığit, Levent Ediş, Mehmet Akif Çakar, Saadet Demirtaş, Ali Tamer\*

Sakarya Eğitim ve Araştırma Hastanesi, Kardiyoloji Kliniği, Sakarya, Türkiye

\*Sakarya Eğitim ve Araştırma Hastanesi, İç Hastalıkları Kliniği, Sakarya, Türkiye

### Abstract

Eisenmenger's syndrome is defined as an irreversible increase in pulmonary vascular resistance and is characterized by right-to-left shunt at the connection point of the pulmonary and systemic circulations. Congenital heart defects including atrial septal defect may result in Eisenmenger's syndrome. Multiple hemostatic abnormalities have been described in patients with congenital heart disease who have cyanosis or pulmonary hypertension due to dysfunction of pulmonary vascular endothelium. In the literature, the association of bleeding diathesis with pulmonary hypertension has been previously reported. In this report, we present a case of recurrent gastrointestinal bleeding in a 54-year-old man with Eisenmenger's syndrome secondary to atrial septal defect. (*The Medical Bulletin of Haseki 2011; 49: 44-6*)

**Key Words:** Gastrointestinal bleeding, Eisenmenger's syndrome, atrial septal defect

### Özet

Eisenmenger sendromu pulmoner vasküler direncin geri dönüşümsüz artışı olarak tanımlanır ve sistemik-pulmoner kan akımı arasındaki bağlantının sağdan sola şant yoluyla sağlanması ile karakterizedir. Atriyal septal defektin de dahil olduğu doğumsal kalp defektleri Eisenmenger sendromuna neden olabilir. Siyanoz veya pulmoner damar yatağının disfonksiyonu sonucu pulmoner hipertansiyonu olan doğumsal kalp hastalıklarında çeşitli kanama bozuklukları tanımlanmıştır. Kanama diyatezi ve pulmoner hipertansiyon arasındaki ilişki literatürde daha önce belirtilmiştir. Bu raporda atriyal septal defekte bağlı oluşan ve tekrarlayan gastrointestinal kanaması olan 54 yaşındaki erkek Eisenmenger sendromlu olguyu sunduk. (*Haseki Tıp Bülteni 2011; 49: 44-6*)

**Anahtar Kelimeler:** Gastrointestinal kanama, Eisenmenger sendromu, atriyal septal defekt

### Introduction

Eisenmenger's syndrome can be described as pulmonary hypertension at the systemic level due to a high pulmonary vascular resistance, with reversed or bidirectional shunting through a large congenital heart defect (1). For example, if an atrial septal defect (ASD) is not treated, increased left-to-right blood shunting causes morphologic changes in the pulmonary vasculature, and because of the effect of increased pulmonary vascular resistance, the shunt

reverses and Eisenmenger's syndrome occurs (2). Multiple hemostatic abnormalities have been described in patients with congenital heart disease who have cyanosis or pulmonary hypertension due to dysfunction of pulmonary vascular endothelium. In the literature, the association between bleeding diathesis and pulmonary hypertension has been previously reported (3-8). In this report, we presented a case of recurrent gastrointestinal bleeding in a patient with Eisenmenger's syndrome secondary to atrial septal defect.

**Address for Correspondence/Yazışma Adresi:** Dr. Hüseyin Gündüz

Sakarya Eğitim ve Araştırma Hastanesi, Kardiyoloji Kliniği, Sakarya, Türkiye

E-mail: drhuseyingunduz@yahoo.com

**Received/Geliş Tarihi:** 24 Ağustos 2010 **Accepted/Kabul Tarihi:** 02 Ocak 2011

The Medical Bulletin of Haseki Training and Research Hospital, published by Galenos Publishing.

*Haseki Tıp Bülteni,*  
Galenos Yayinevi tarafından basılmıştır.

## Case Report

A 54-year old man was admitted to our clinic with progressive dyspnea (New York Heart Association class III-IV) that has lasted for four years and blood in his stool. He had a previous history of secundum ASD and pulmonary hypertension. Right heart catheterization performed nine years ago had showed decreased left to right shunt ( $Q_p/Q_s=1.1$ ), high pulmonary vascular resistance (10 woods unit/ $m^2$ ) and significant pulmonary hypertension; with this findings, the patient was considered inoperable. His medical history revealed recurrent gastrointestinal bleeding five times within the last six years and hemorrhagic cerebrovascular accident 4 years ago. The initial physical examination demonstrated respiratory distress, 80% oxygen saturation, peripheral cyanosis, oral temperature of 37.0°C, blood pressure of 140/90 mm Hg, and heart rate of 107 bpm. No significant orthostatic changes were noted in pulse rate and blood pressure of the patient. His respiratory rate was 24 breaths/min, with mildly increased work of breathing. His jugular venous pressure was elevated and the lungs were clear to auscultation that showed a widely fixed splitting of the second heart sound which varied little with respiration, and a mild systolic murmur. The peripheral arterial pulses in the upper and lower extremities were palpable. The rectal examination revealed black, tarry feces in the rectum.

His ECG demonstrated right-axis deviation, right bundle branch block and right ventricular hypertrophy. His chest radiography showed an enlarged cardiopericardial silhouette. The patient's cardiac enzyme examination was within normal limits. His medical history revealed recurrent gastrointestinal bleeding and hemorrhagic cerebrovascular accident. Thus, we performed detailed coagulometric tests, revealing hemoglobin level of 18.1 g/dL, hematocrit level of 55.3%, platelet count of  $180 \times 10^3/\mu L$ , prothrombin time of 16.6 seconds, and partial thromboplastin time of 32.3 seconds. In vitro bleeding time (collagen/epinephrine) was normal. Vitamin K-dependent factors; factor VII 39% (70-130) was decreased and factor IX 71% (60-150) was normal, vWF antigenic activity 184% (50-160) and factor VIII 153% (60-150) were increased but vWF-ristocetin cofac-

tor activity 120% (50-150) was normal. The liver enzyme levels were within normal limits. Endoscopic biopsy was performed from the ulcer margin.

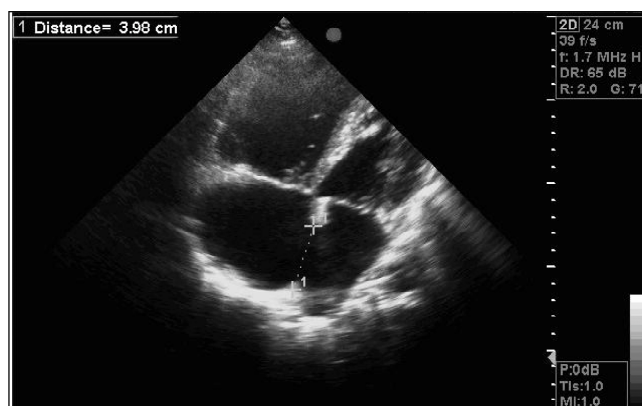
Transthoracic echocardiography demonstrated a large secundum ASD with size 37 mm (Figure 1) and dilatation in the right heart chambers, severe tricuspid regurgitation, and severe pulmonary arterial hypertension (pulmonary artery systolic pressure-90 mmHg). Contrast M-mode echocardiogram with peripheral venous injections was performed and right-to-left shunt was detected (Figure 2). An upper endoscopy revealed an ulcer at the anterior wall of bulbous and bulky ulcer margins (Figure 3).

The patient was treated medically as surgical closure of the ASD was contraindicated at this late stage according to the right heart catheterization performed nine years ago. In the treatment of upper gastrointestinal bleeding, intravenous pantoprazole was used as 80-mg bolus followed by 8-mg/h infusion. The infusion was continued for 48 hours. The 6-minute walking test was performed prior to discharge. The patient was able to walk only for 2.5 min and covered a distance of 80 m. The test was ended because of aggravation of cyanosis and decrease in oxygen saturation from 80% to 70%. Bosentan (2x31.25 mg) was started together with chronic diltiazem and furosemid treatment. The patient was discharged. Bosentan dose was to be increased to 2x62.5 mg at the end of the first month on polyclinic control.

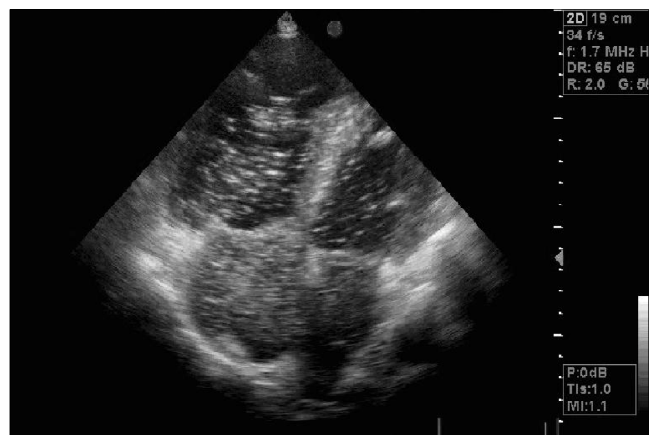## Discussion

The Eisenmenger's syndrome is defined as an irreversible increase in pulmonary vascular resistance and is characterized by right to-left-shunt at the connection point of the pulmonary and systemic circulations (9). Congenital heart defects may result in Eisenmenger's syndrome including ventricular septal defect, patent ductus arteriosus, atrial septal defect, d-transposition of the great vessels, and surgically created aortapulmonary connections (10).

In patients with atrial septal defect, blood initially shunts from the systemic to the pulmonary circulation, and if the defect is large and the left-to-right shunting is sustained,



**Figure 1.** Two-dimensional echocardiographic view demonstrating atrial septal defect, right atrial and ventricular enlargement

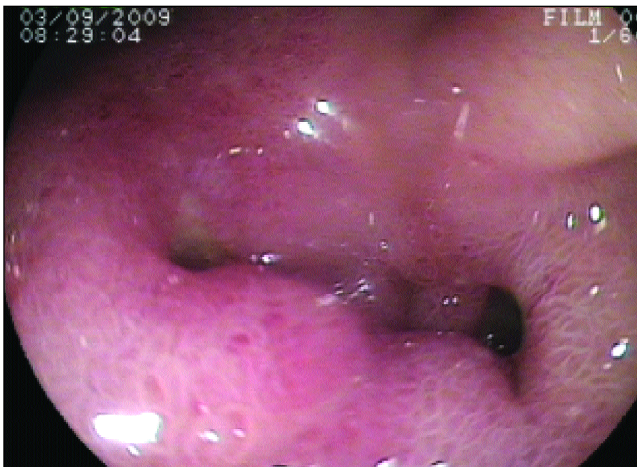

**Figure 2.** Contrast echocardiography demonstrating right-to-left shunt

exposure of the pulmonary vasculature to systemic arterial pressure, or increased blood flow leads to progressive morphologic changes in the microvasculature with resultant obliteration of pulmonary arterioles and capillaries, and increased pulmonary vascular resistance. Finally, pulmonary vascular resistance and pulmonary arterial pressure approach systemic vascular resistance and systemic arterial pressure, and the shunt reverses (2).

Multiple hemostatic abnormalities have been described in patients with congenital heart disease, who have cyanosis or pulmonary hypertension, including thrombocytopenia, prolonged bleeding, prothrombin or partial thromboplastin times, deficiency in vitamin K-dependent clotting factors, and abnormal fibrinolysis (3-5). Although the cause of these defects is not completely understood, an acquired type II-like von Willebrand factor abnormality-presumably from defective synthesis or abnormal degradation of von Willebrand factor by dysfunctional pulmonary vascular endothelium-has been described and may partially account for bleeding diathesis (6-8). According to Rabinovitch M. and friends, vWF synthesis would be increased in patients with pulmonary hypertension, in particular the group with associated congenital heart defects. This might contribute to abnormal interactions with platelets, which may result in increased adherence, increased release of vasoactive substances and smooth muscle mitogens, and worsening of the pulmonary hypertension (6). Another hypothesis presented by Gill and friends suggests that abnormal hemodynamic flow was associated with activation of platelets or endothelial cells with resultant adsorption of the largest vWF multimers from the plasma (7). Another possible mechanism for the phenomenon is cleavage of the vWF multimers into smaller forms by proteolytic enzymes (possibly by plasmin) and/or the calcium-activated protease similar to that described in patient with disseminated intravascular coagulation (11-13).

In addition; Lopes et al. (8) speculated that local protease activation at sites of pulmonary vascular injury may account for abnormal degradation of vWF and possibly other proteins.



**Figure 3.** Endoscopic imaging of ulcer on the anterior wall of bulbus

In the three presented research; pulmonary hypertensive patients had increased vWF:Ag values, but the biological activity of vWF (vWF:RiCoF activity) had decreased because of the loss of high-molecular-weight-forms. In our study, we found increased vWF-Ag and factor VIII with normal value of biological activity.

In the study of Henriksson et al. (3) low levels of factor II, VII and X were found in patients with cyanotic congenital heart disease, and the haemostatic defects, especially decreased vitamin K dependent factors (protrombin, faktör VII and IX) can be explained by deficient liver synthesis resulting from systemic hypoxia as well as from sluggishness of the local microcirculation caused by high blood viscosity. In our study factor VII was decreased and factor IX was normal.

To our knowledge, this is the first case report of recurrent gastrointestinal bleeding due to Eisenmenger syndrome secondary to ASD. This report shows us that, frequency of bleeding complications, especially in the gastrointestinal system may be increased according to hemostatic defects in Eisenmenger's syndrome. In our opinion, detailed assessment should be performed particularly in cyanotic patients with recurrent bleeding episodes.

## Kaynaklar

1. Wood P. The Eisenmenger syndrome or pulmonary hypertension with reversed central shunt. *Br Med J* 1958;2:701-9.
2. Heath D, Edwards JE. The pathology of hypertensive pulmonary vascular disease. A description of six grades of structural changes in the pulmonary arteries with special reference to congenital cardiac septal defects. *Circulation* 1958;18:533-47.
3. Henriksson P, Varendh G, Lundstrom NR. Haemostatic defects in cyanotic congenital heart disease. *Br Heart J* 1979;41:23-7.
4. Colon-Otero G, Gilchrist GS, Holcomb GR, Ilstrup DM, Bowie EJ. Preoperative evaluation of hemostasis in patients with congenital heart disease. *Mayo Clin Proc* 1987;62:379-85.
5. Altman R, Scazzio A, Rouvier J, et al. Coagulation and fibrinolytic parameters in patients with pulmonary hypertension. *Clin Cardiol* 1996;19:549-54.
6. Rabinovitch M, Andrew M, Thorn H, et al. Abnormal endothelial factor VIII associated with pulmonary hypertension and congenital heart defects. *Circulation* 1987;76:1043-52.
7. Gill JC, Wilson AD, Endres-Brooks J, Montgomery RR. Loss of the largest von Willebrand factors multimers from the plasma of patients with congenital cardiac defects. *Blood* 1986;67:758-61.
8. Lopes AA, Maeda NY. Abnormal degradation of von Willebrand factor main subunit in pulmonary hypertension. *Eur Respir J* 1995;8:530-6.
9. Adatia I. Recent advances in pulmonary vascular disease. *Curr Opin Pediatr* 2002;14:292-7.
10. Kidd L, Driscoll DJ, Gersony WM, et al. Second natural history study of congenital heart defects. Results of treatment of patients with ventricular septal defects. *Circulation* 1993;87:38-51.
11. Kirby EP, Martin N, Marder VJ. Degradation of bovine factor VIII 4by plasmin and trypsin. *Blood* 1974;43:629-40.
12. McKee PA, Anderson JC, Switzer ME. Molecular structural studies of human factor VIII. *Ann NY Acad Sci* 1975;240:8-33.
13. Switzer ME, McKee PA. Studies on human antihemophilic factor: Evidence for a covalently linked subunit structure. *J Clin Invest* 1976;57:925-37.